HOKKAIDO UNIVERSITY

Title	Acquisition of monosomy 7 and a RUNX1 mutation in Pearson syndrome
Author(s)	Nishimura, Akira; Hirabayashi, Shinsuke; Hasegawa, Daisuke et al.
Citation	Pediatric blood & cancer, 68(2), e28799 https://doi.org/10.1002/pbc.28799
Issue Date	2021-02
Doc URL	https://hdl.handle.net/2115/84042
Rights	This is the peer reviewed version of the following article: Nishimura, A, Hirabayashi, S, Hasegawa, D, et al. Acquisition of monosomy 7 and a RUNX1 mutation in Pearson syndrome. Pediatr Blood Cancer. 2021; 68:e28799, which has been published in final form at https://doi.org/10.1002/pbc.28799. This article may be used for non-commercial purposes in accordance with Wiley Terms and Conditions for Use of Self-Archived Versions
Type	journal article
File Information	Pediatr Blood Cancer_68_e28799.pdf

Hokkaido University Collection of Scholarly and Academic Papers : HUSCAP

Acquisition of monosomy 7 and a *RUNX1* mutation in Pearson syndrome

Akira Nishimura[1,2], Shinsuke Hirabayashi[1,3], Daisuke Hasegawa[1], Kenichi Yoshida[4], Yuichi Shiraishi[5], Miho Ashiarai[1], Yosuke Hosoya[1], Tohru Fujiwara[6], Hideo Harigae[6], Satoru Miyano[5], Seishi Ogawa[4,7,8] and Atsushi Manabe[1,3]

[1]Department of Pediatrics, St. Luke's International Hospital, Tokyo, Japan; [2]Department of Pediatrics and Developmental Biology, Tokyo Medical and Dental University, Tokyo, Japan; [3]Department of Pediatrics, Hokkaido University Graduate School of Medicine, Sapporo, Japan; [4]Department of Pathology and Tumor Biology, Graduate School of Medicine, Kyoto University, Kyoto, Japan; [5]Laboratory of DNA Information Analysis, Human Genome Center, Institute of Medical Science, University of Tokyo, Tokyo, Japan; [6]Department of Hematology and Rheumatology, Tohoku University Graduate School, Sendai, Japan; [7]Institute for the Advanced Study of Human Biology (WPI ASHBi), Kyoto University, Kyoto, Japan; [8]Department of Medicine, Center for Hematology and Regenerative Medicine, Karolinska Institute, Stockholm, Sweden

Correspondence to:
Shinsuke Hirabayashi, MD
Department of Pediatrics,
Hokkaido University Graduate School of Medicine, Sapporo, Japan
Kita 15, Nishi 7, Kita-ku, Sapporo, 060-8638, Japan
Phone:+81-11-706-5954 Fax:+81-11-706-7898 E-mail: hirabayashi-slh@umin.ac.jp

Word count: abstract: 97; Manuscript: 1,230; Reference 25; Table: 1; Figure 1.
Keywords: Monosomy 7, *RUNX1*, Pearson syndrome
Running head: Monosomy 7 and *RUNX1* mutation in PS

Abbreviations	
BM	bone marrow
HSCT	hematopoietic stem cell transplantation
IBMFS	inherited bone marrow failure syndrome
MDS	myelodysplastic syndrome
mtDNA	mitochondrial DNA
PS	Pearson syndrome
WES	whole exome sequencing

ABSTRACT

Pearson syndrome (PS) is a very rare and often fatal multisystem disease caused by deletions in mitochondrial DNA that result in sideroblastic anemia, vacuolization of marrow precursors, and pancreatic dysfunction. Spontaneous recovery from anemia is often observed within several years of diagnosis. We present the case of a 4-month-old male diagnosed with PS who experienced prolonged severe pancytopenia preceding the emergence of monosomy 7. Whole-exome sequencing identified two somatic mutations including *RUNX1* p.S100F that was previously reported as associated with myeloid malignancies. The molecular defects associated with PS may have the potential to progress to advanced MDS.

INTRODUCTION

Pearson syndrome (PS) is a multi-organ system disorder characterized by refractory sideroblastic anemia with vacuolization of bone marrow (BM) precursors, lactic acidosis and exocrine pancreatic dysfunction that result from the deletion of mitochondrial DNA (mtDNA) sequences. Pancreatic dysfunction frequently accompanies PS but it is not critical for the diagnosis.[1,2] The incidence of PS is very low, at approximately one case per million individuals.[3] PS is one of the disorders to be considered in the differential diagnosis of hypocellular BM in young children.[4,5] It is not clear whether PS is associated with malignant transformation; the long-term prognosis of PS is generally poor, as children often succumb to fatal lactic acidosis.[6]

Monosomy 7 is a common cytogenetic abnormality identified in inherited BM failure syndromes (IBMFS) and pediatric myelodysplastic syndrome (MDS).[7] The basic mechanisms underlying the acquisition of monosomy 7, including haplo-insufficiency and related somatic events, have been explored previously.[8] Here we describe a case of a patient diagnosed with PS who experienced prolonged and severe pancytopenia followed by the emergence of monosomy 7 and a somatic mutation in *RUNX1* underwent hematopoietic stem cell transplantation (HSCT).

METHODS

Written informed consent from the guardians of the patient was obtained for sample storage and analyses. The analyses were conducted in accordance with the Declaration of Helsinki. DNA from BM cells obtained from the patient at diagnosis and again upon development of pancytopenia were subjected to whole-exome sequencing (WES); DNA from buccal cells was used as a germline control. Whole-exome capture was performed using SureSelect Human All Exon Kit V6 (Agilent Technology, Santa Clara, CA, USA). Captured targets were subjected to sequencing using a HiSeq 2000 (Illumina, San Diego, CA, USA). With mean depths of 114-143x, sequence alignments and mutation identifications were performed using our in-house Genomon program, as previously described.[9] Candidate mutations were identified with the following filters: (i) P-value < $10^{-1.3}$ (by Fisher's test); (ii) EB call (Empirical Bayesian mutation calling)[10] P-value < 10^{-4}; (iii) variant allele frequency in normal sample < 0.02. Copy number analysis was performed using in-house program known as CNACS[11] (https://github.com/papaemmelab/toil_cnacs). Frequency of deletion in mtDNA was

calculated as mean depth of mtDNA with deletion detected (MT:8,469–13,446) divided by those without (MT:1–8,468).

RESULTS AND DISCUSSION

A 4-month-old boy was admitted for treatment of respiratory syncytial virus infection and mild pancytopenia. There was no past medical history or any notable family history. Examination of the BM was notable for vacuolated myeloid and erythroid precursors with ring sideroblasts. Chromosomal analysis revealed 46,XY in 20 out of 20 metaphase spreads. Blood levels of lactic acid were elevated; as such, genetic testing was performed. A large deletion of mtDNA was detected, which indicates a diagnosis of PS. The deleted mtDNA allele was detected at a frequency 81% in BM as a consequence of heteroplasmy that was identified by WES with off-target sequencing reads on mtDNA (Figure 1a). No somatic mutations were detected in BM cells at diagnosis.

The patient began a series of regular red blood cell transfusions to treat his anemia. At the age of 22 months, BM examination revealed significant hemophagocytosis after a respiratory tract infection that resolved in response to prednisolone. Profound

thrombocytopenia and neutropenia emerged at the age of 30 months. Platelets counts were fluctuating with regular transfusion. Absolute neutrophil counts was stable around 300 /μL. BM examination revealed hypo-cellular marrow with 2 % of myeloblasts and minimal dysplasia. A repeat chromosomal analysis revealed a 45,XY, −7 [12]/ 45, idem, t(4;21)(p11;q22) [4]/ 46, XY [4] aberration; monosomy 7 was also in 38% of the cells by fluorescent *in situ* hybridization and WES (Figure 1b). Furthermore, WES revealed two somatic mutations of *RUNX1* and *LINGO4* in addition to monosomy 7 (Table 1). *RUNX1* p.S100F mutation was previously reported in myeloid malignancies.[12] The frequency of mtDNA deletion was 78%. The patient received an unrelated cord blood transplantation at the age of 42 months to treat prolonged pancytopenia. The conditioning regimen included anti-thymocyte globulin, fludarabine, and melphalan from HLA fully matched (8/8) unrelated cord blood. Lactic acidosis deteriorated with infusion reaction by anti-thymocyte globulin. Neutrophil engraftment was obtained on day 20. Acute GVHD of skin (stage 3) and liver (stage 1) were resolved with prednisolone. He was discharged on day 66. His hematological status and acid-base balance are stable 20 months after HSCT.

The proportion of deleted mtDNA in hematopoietic cells of patients diagnosed with PS varies due to heteroplasmy; the severity of hematologic manifestations is directly related to this phenomenon. Cytopenia associated with PS may resolve spontaneously with a decreasing frequency of mitochondria with deleted mtDNA.[13,14] Our patient did not experience any resolution of his anemia; the ratio of deleted to intact mtDNA did not change over time as assessed by WES. In addition to persistent BM failure, monosomy 7 appeared two years after initial diagnosis. PS is important as a differential diagnosis of IBMFS, however it is considered to be a non-hematological disorder. Actually, development of cytogenetic abnormalities was previously reported in three cases of PS; all cases had chromosome 7 related abnormalities. The clinical course varied from transient abnormalities to progression AML.[4, 15,16]

Monosomy 7 occurs during the clonal evolution to MDS/leukemia in a variety of IBMFSs.[7] MDS with monosomy 7 in children has been associated with a high risk of disease progression.[17] Among those cohorts, patients with germline *SAMD9/9L* mutations also frequently developed monosomy 7 as a consequence of an adaptation-by-aneuploidy mechanism.[18] *SAMD9/9L* locate on chromosome 7, and their mutations have growth-restricting activity. WES confirmed that our patient harbored no known

germline abnormalities including *SAMD9/9L, GATA2 and FANC genes* that would suggest a predisposition to MDS. Acquisition and selection of monosomy 7 clones may be caused with a similar mechanism in patients with BM failure[7] where the hematopoietic milieu is exposed to cytopenia-induced stress. Of note, our patient did not undergo treatment with G-CSF, which is known to be associated with the development of monosomy 7 in patients with BM failure.[19]

Acquisition of additional genetic abnormalities predicts disease progression in adult MDS.[20] One study showed that MDS in children was often associated with Ras/MAPK pathway mutations; by contrast, children with germline *SAMD9/9L* mutations rarely acquired additional gene or chromosomal alterations.[21] Monosomy 7 itself results in haplo-insufficiency of tumor suppressor genes on chromosome 7, which could cooperate with other driver events in modulating the pathogenesis of myeloid malignancies. For example, loss of *EZH2* (located on 7q36) has been shown to interact with *RUNX1* mutations and to generate myeloid tumors in mice.[22] Somatic mutations in *RUNX1* are reported frequently in association with childhood MDS with monosomy 7.[23] In IBMFSs, including Fanconi anemia and severe congenital neutropenia, the combination of *RUNX1* mutations and monosomy 7 also contribute

to myeloid leukemogenesis.[24,25] Of note, a *RUNX1* mutation that has been associated with myeloid malignancies was also identified in our patient. This clone might have had the potential to progress to advanced MDS.

The cases of two patients with PS who received unrelated HSCT were previously described in the literatures.[15,16] In one patient, both hematological and non-hematological manifestations resolved in response to this intervention,[16] similar to that observed in our case. PS has features of fatal multisystem dysfunction and spontaneous recovery from anemia within several years of diagnosis. Although HSCT can result in serious complications, it may be a feasible option for patients with severe PS who acquired cytogenetically abnormalities in BM and should be considered in a future prospective clinical trial.

Acknowledgements

This work was supported by the Japan Society for the Promotion of Science (JSPS) through Grants-in-Aid for Scientific Research (KAKENHI), grant number (16K21376 and 18K16128 to S.H, JP26221308 and JP19H05656 to S.O) and also by the Japan

Agency for Medical Research and Development (AMED); the Project for Development of Innovative Research on Cancer Therapeutics (JP 20cm0106501h0005 to S. O.).

Authorship Contributions

Conception and design: A.N, S.H., D.H., and A.M. Data analysis and interpretation: all authors. Manuscript writing and final approval: all authors.

Disclosure of Conflicts of Interest

All authors declare that there are no conflicts of interest.

References

1. Pearson HA, Lobel JS, Kocoshis SA, et al. A new syndrome of refractory sideroblastic anemia with vacuolization of marrow precursors and exocrine pancreatic dysfunction. *J Pediatr.* 1979;95(6):976-984.
2. Rotig A, Colonna M, Bonnefont JP, et al. Mitochondrial DNA deletion in Pearson's marrow/pancreas syndrome. *Lancet.* 1989;1(8643):902-903.
3. Farruggia P, Di Cataldo A, Pinto RM, et al. Pearson Syndrome: A Retrospective Cohort Study from the Marrow Failure Study Group of A.I.E.O.P. (Associazione Italiana Emato-Oncologia Pediatrica). *JIMD Rep.* 2016;26:37-43.
4. Gagne KE, Ghazvinian R, Yuan D, et al. Pearson marrow pancreas syndrome in patients suspected to have Diamond-Blackfan anemia. *Blood.* 2014;124(3):437-440.
5. Niemeyer CM, Baumann I. Classification of childhood aplastic anemia and myelodysplastic syndrome. *Hematology / the Education Program of the American Society of Hematology American Society of Hematology Education Program.* 2011;2011:84-89.
6. Yoshimi A, Grünert SC, Cario H, et al. Hematological presentation and change in clinical phenotype during follow-up in Pearson syndrome. *Blood*. 2019:134 (Supplement_1):3746.
7. Wlodarski MW, Sahoo SS, Niemeyer CM. Monosomy 7 in Pediatric Myelodysplastic Syndromes.

Hematol Oncol Clin North Am. 2018;32(4):729-743.

8. Inaba T, Honda H, Matsui H. The enigma of monosomy 7. *Blood.* 2018;131(26):2891-2898.

9. Yokoyama A, Kakiuchi N, Yoshizato T, et al. Age-related remodelling of oesophageal epithelia by mutated cancer drivers. *Nature.* 2019;565(7739):312-317.

10. Shiraishi Y, Sato Y, Chiba K, et al. An empirical Bayesian framework for somatic mutation detection from cancer genome sequencing data. *Nucleic Acids Res.* 2013;41(7):e89.

11. Yoshizato T, Nannya Y, Atsuta Y, et al. Genetic abnormalities in myelodysplasia and secondary acute myeloid leukemia: impact on outcome of stem cell transplantation. *Blood.* 2017;129(17):2347-2358.

12. Papaemmanuil E, Gerstung M, Bullinger L, et al. Genomic Classification and Prognosis in Acute Myeloid Leukemia. *The New England journal of medicine.* 2016;374(23):2209-2221.

13. Muraki K, Nishimura S, Goto Y, Nonaka I, Sakura N, Ueda K. The association between haematological manifestation and mtDNA deletions in Pearson syndrome. *J Inherit Metab Dis.* 1997;20(5):697-703.

14. Yanagihara I, Inui K, Yanagihara K, et al. Fluorescence in situ hybridization analysis of peripheral blood cells in Pearson marrow-pancreas syndrome. *J Pediatr.* 2001;139(3):452-455.

15. Faraci M, Cuzzubbo D, Micalizzi C, et al. Allogeneic bone marrow transplantation for Pearson's

syndrome. *Bone Marrow Transplant.* 2007;39(9):563-565.

16. Hoyoux C, Dresse MF, Robinet S, et al. Cord blood transplantation in a child with Pearson's disease. *Pediatr Blood Cancer.* 2008;51(4):566.

17. Kardos G, Baumann I, Passmore SJ, et al. Refractory anemia in childhood: a retrospective analysis of 67 patients with particular reference to monosomy 7. *Blood.* 2003;102(6):1997-2003.

18. Narumi S, Amano N, Ishii T, et al. SAMD9 mutations cause a novel multisystem disorder, MIRAGE syndrome, and are associated with loss of chromosome 7. *Nature genetics.* 2016;48(7):792-797.

19. Ohara A, Kojima S, Hamajima N, et al. Myelodysplastic syndrome and acute myelogenous leukemia as a late clonal complication in children with acquired aplastic anemia. *Blood.* 1997;90(3):1009-1013.

20. Makishima H, Yoshizato T, Yoshida K, et al. Dynamics of clonal evolution in myelodysplastic syndromes. *Nature genetics.* 2017;49(2):204-212.

21. Schwartz JR, Ma J, Lamprecht T, et al. The genomic landscape of pediatric myelodysplastic syndromes. *Nat Commun.* 2017;8(1):1557.

22. Sashida G, Harada H, Matsui H, et al. Ezh2 loss promotes development of myelodysplastic syndrome but attenuates its predisposition to leukaemic transformation. *Nat Commun.* 2014;5:4177.

23. Pastor V, Hirabayashi S, Karow A, et al. Mutational landscape in children with myelodysplastic syndromes is distinct from adults: specific somatic drivers and novel germline variants. *Leukemia.* 2017;31(3):759-762.

24. Quentin S, Cuccuini W, Ceccaldi R, et al. Myelodysplasia and leukemia of Fanconi anemia are associated with a specific pattern of genomic abnormalities that includes cryptic RUNX1/AML1 lesions. *Blood.* 2011;117(15):e161-170.

25. Skokowa J, Steinemann D, Katsman-Kuipers JE, et al. Cooperativity of RUNX1 and CSF3R mutations in severe congenital neutropenia: a unique pathway in myeloid leukemogenesis. *Blood.* 2014;123(14):2229-2237.

TABLE AND FIGURE LEGENDS

Table 1.

Mutations identified by whole-exome sequencing.

Figure 1.

Deletion in mtDNA and monosomy 7 detected by whole-exome sequencing.

a) Deletion in mtDNA. Sequencing depth on mtDNA are displayed in gray using IGV for samples at diagnosis and after the development of pancytopenia as well as a control sample. Colored positions mean the positions where alleles different from the reference sequence were called.

b) Monosomy 7 after the development of pancytopenia. Total copy number (CN) and allele specific (AS) CN of chromosome 7 are shown for samples at diagnosis and after the development of pancytopenia.

Figure 1

a

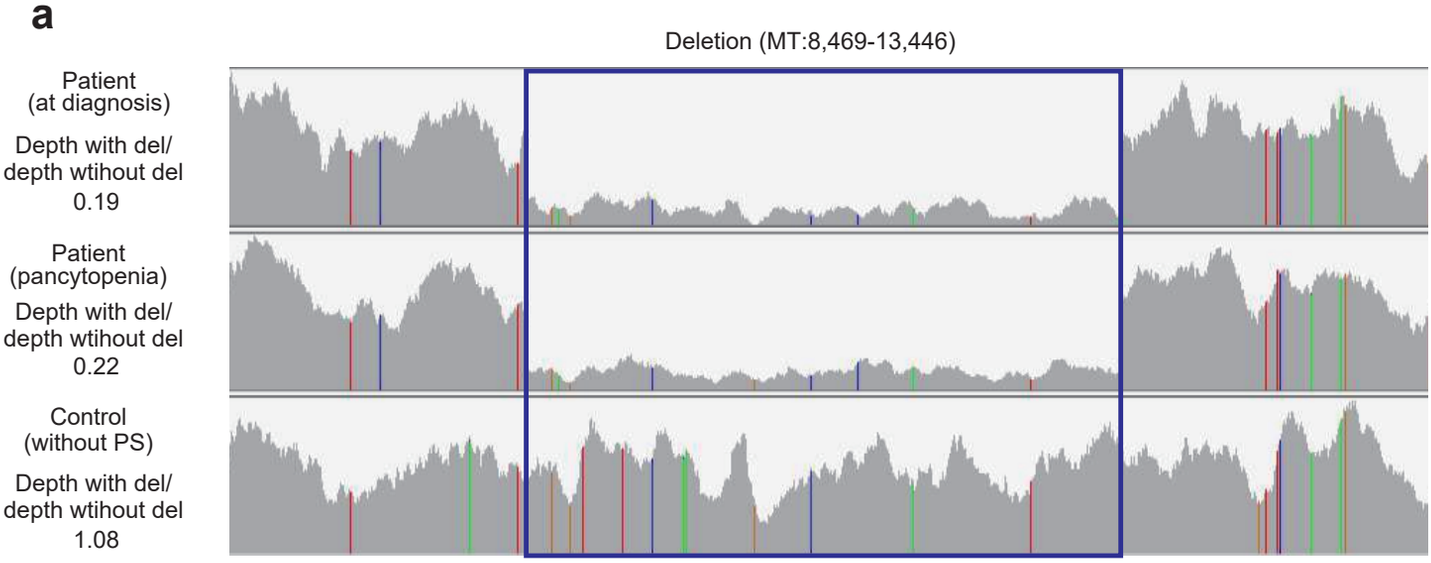
Deletion (MT:8,469-13,446)
Patient
(at diagnosis)
Depth with del/
depth wtihout del
0.19
Patient
(pancytopenia)
Depth with del/
depth wtihout del
0.22
Control
(without PS)
Depth with del/
depth wtihout del
1.08

b

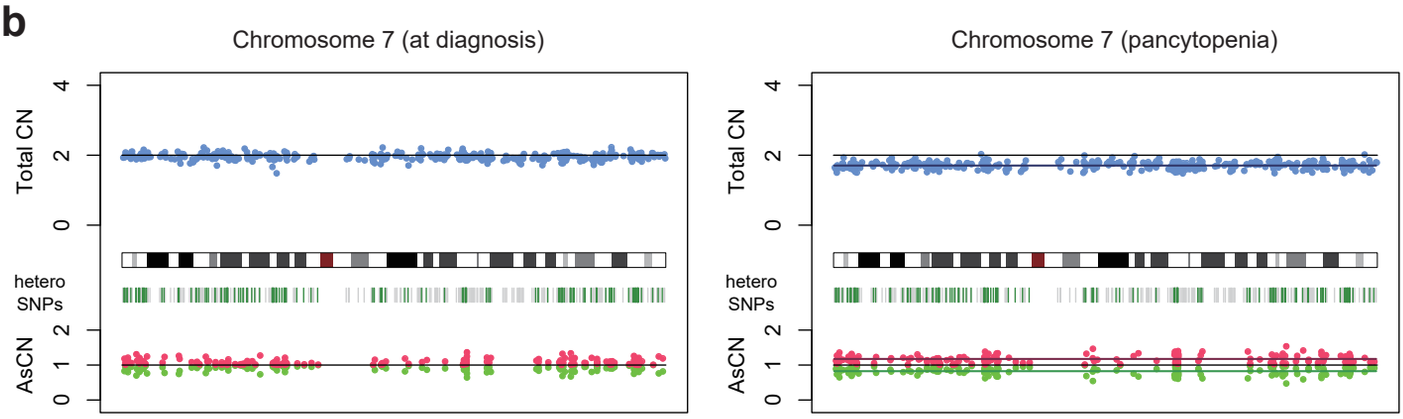
Chromosome 7 (at diagnosis)
Chromosome 7 (pancytopenia)
Total CN
hetero
SNPs
AsCN
0
2
4
1

Table 1. Mutations identified by whole exome sequencing

Chr	Start	End	Ref	Alt	Gene	Exonic function	Amino acid change	VAF_tumor	VAF_normal
21	36259192	36259192	G	A	*RUNX1*	Missense SNV	NM_001754:exon4:c.C299T:p.S100F	0.086	0
1	151774970	151774970	G	A	*LINGO4*	Missense SNV	NM_001004432:exon2:c.C211T:p.R71C	0.032	0